

MICROSURGICAL APPROACH FOR THE MANAGEMENT OF MULTIPLE GINGIVAL RECESSION BY TUNNEL-POUCH TECHNIQUE WITH COMBINATION OF SUBEPITHELIAL CONNECTIVE TISSUE GRAFT

Ranjana Mohan,¹ Janardhana Amaranath BJ,² Karthik Krishna M³, Rohit Jain⁴

Professor & Head,¹ Professor,² Reader,³ Senior Lecturer⁴

1-4 Department of Periodontology, Teerthanker Mahaveer Dental College & Research Centre, Moradabad.

Abstract

Gingival architecture forms one of the important components of facial esthetics and presence of recession can mar a good smile. The periodontist can employ various periodontal plastic microsurgery procedures for management of gingival recession and restore esthetics. A 29-year-old patient reported with the chief complaint of long looking teeth in the upper jaw, making him conscious while smiling. A Miller's class I gingival recession in relation to maxillary left incisors was diagnosed. Periodontal plastic microsurgery employing tunnel pouch with combined epithelialized – subepithelial connective tissue graft in order to cover denuded root was performed under magnification. Healing was uneventful, with achievement of nearly complete root coverage.

Key Words: Connective Tissue Graft, Esthetics, Gingival Recession, Microsurgery, Microsuturing

Introduction

Smile is the key component of esthetics possessing an important role in the determination of first impression of a person and an ideal gingival architecture is a prerequisite for a perfect smile. Presence of gingival recession, defined as “an apical displacement of soft tissues related to the cemento-enamel junction”, can hamper the esthetics of an individual.^{1,2}

Alveolar bone and gingival recessions are predominantly found on the buccal root prominences, especially at premolar and canine sites, where bone dehiscences and fenestrations seem to be a common morphological feature.³ Such anatomical variations have frequently been identified and their prevalence and severity appear to be age-dependent.⁴⁻⁸ According to some assumptions the lesions may be classified into (1) traumatic injuries mainly owing to excessive and/or inadequate tooth brushing techniques and (2) inflammatory reactions of the gingiva as a result of plaque accumulation⁶ and combinations thereof.⁹⁻¹⁰

As aesthetic aspects represent an inseparable part of today's clinical practice, the surgical coverage of recessions is mainly indicated for aesthetic improvement rather than functional aspects.¹¹ However, further indications for surgical coverage of exposed roots include dental hypersensitivity, root caries and in situations where proper plaque control may be limited by an unfavourable contour of the gingival margin.¹²

Gingival recession has been treated with a variety of techniques depending upon whether the recession was generalized or on an isolated tooth. Difficult situations such as multiple surfaces of root recession, especially in the maxilla where the surfaces of the teeth are wide, have long been a cosmetic enigma. A multitude of procedures have been devised and performed for attaining root coverage in multiple recessions with varying levels of success. One of the procedures capable of achieving near complete root coverage is the pouch and tunnel method combined with a connective tissue graft.

Case Report

A 29-year-old male patient reported to the Department of Periodontology at Teerthanker Mahaveer Dental College and Research Centre, Moradabad, Northern India, with the chief complaint of long looking teeth in the upper jaw. The patient was particularly concerned regarding his esthetic appearance when smiling. After obtaining the patients consent thorough medical and dental histories were taken. Intraoral examination revealed generalized Millers class I gingival recession (Figure 1).

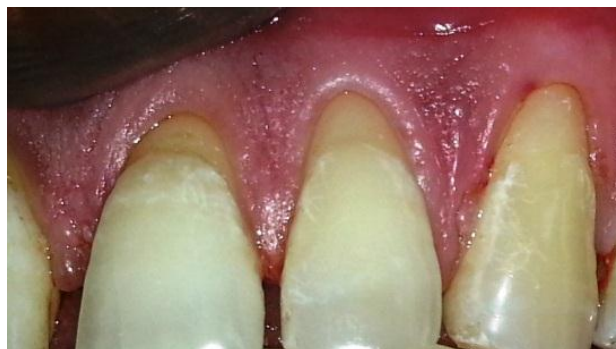

Figure 1: - Miller class I gingival recession in relation to maxillary left incisors and canine.

After thorough assessment of the clinical findings and the patients' requirements, a treatment plan was prepared involving a pouch and tunnel technique combined with an epithelialized – sub-epithelial connective tissue graft in relation to maxillary left incisors and canine on trial basis. Thorough scaling was performed in the initial visit and the patient was recalled after a week for the root coverage procedure. On the second visit, the patient was prepared for surgery after administration of nerve block and local infiltration anaesthesia. The entire procedure was performed under 7.5X magnification utilizing prism telescopic loupes. Sulcular incisions were given to create pouches and tunnel was prepared (Figure 2).

The root surfaces were thoroughly planed and conditioned with 150 mg/ml tetracycline solution. The CT graft was harvested from the hard palate in relation to right premolar

region using a trapdoor technique (Figure 3). The graft tissue was trimmed to the required dimensions and inserted into the tunnel and secured to the recipient bed and adjacent gingival tissue with 8-0 Vicryl™ sutures (Figure 4). The surgical site was dressed with Coepak™ and patient was prescribed analgesic and antibiotic for 10 days.

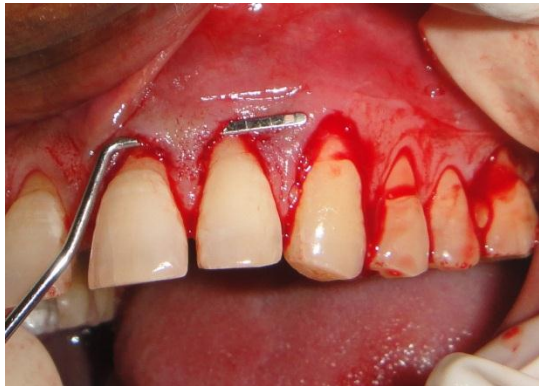

Figure 2: - Creation of pouches and making a tunnel in the gingival tissue.

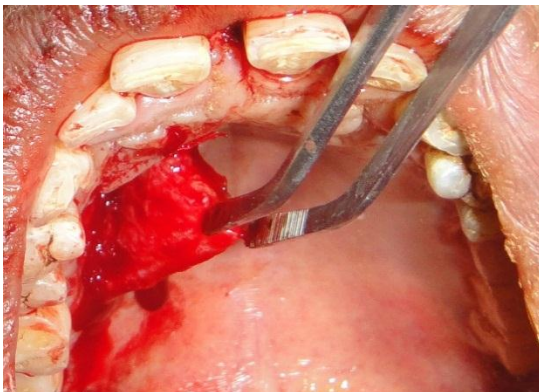


Figure 3: - Harvesting of subepithelial connective tissue graft from palate

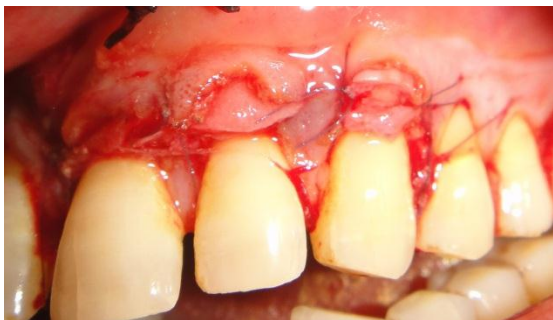

Figure 4: - Connective tissue graft secured in place covering the gingival recession with 8-0 sutures

On observation during the recall visit after 10 days, the surgical site revealed complete root coverage in relation to the incisors and canine (Figure 5). The patient was followed up to a period on 6 months during which negligible amount of recession could be observed (Figure 6).

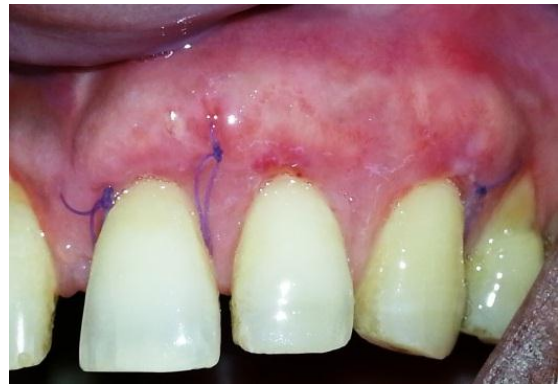

Figure 5: - 10 days post-operative healing showing near complete root coverage

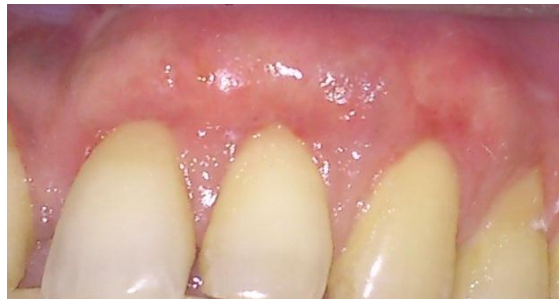

Figure 6: - 6 months post-operative healing. Complete coverage of gingival recession

Discussion

Although numerous approaches for covering denuded root surfaces have been proposed, difference of opinions prevails among clinicians concerning which procedures are most effective.¹³⁻¹⁴ In the 1990s, techniques were described where the roots were covered using the tunnel technique and only sulcular incisions.⁷⁻¹² Therefore, scars from vertical releasing incisions were avoided, and wound healing was facilitated without raising a flap. Raetzke and Allen described techniques in which a tunnel was created only for introducing the graft without coronal advancement. Therefore, the portion of the graft that covers the recession was not covered by the flap and as nutrients for this exposed portion come from the lateral and apical portions of the graft, keratinization may result because of secondary wound healing and lateral migration of epithelial cells.^{13,14}

To overcome these drawbacks, a technique utilizing pouch-tunnel and a combination epithelialized-sub-epithelial connective tissue graft was attempted in this case with an objective to prevent secondary healing. Based on the post-operative findings, it can be considered that complete root coverage was achieved with minimal recession in the long-term. One drawback of this particular procedure was that it resulted in significant increase in the bulk of gingival tissue. However, if required, this excess tissue can be easily trimmed with a minor gingivoplasty procedure.

Conclusion

Based on the long-term post-operative observation of this case, it can be concluded that pouch-tunnel with a combination epithelialized-sub-epithelial connective tissue graft is an effective technique. Further clinical studies are required to establish it as an ideal procedure for achieving complete root coverage in multiple recessions.

References

1. Rocuzzo M, Bunino M, Needleman I, Sanz M. Periodontal plastic surgery for treatment of localized gingival recession: a systematic review. *J Clin Periodontol* 2002;29(3):178-194.
2. The American academy of periodontology: GPT; 3rd Edition.; Chicago 1992.
3. Larato DC. Alveolar plate fenestrations and dehiscences in the human skull. *Oral Surg Oral Med Oral Path* 1970;29(6): 816–819.
4. Sangnes G, Gjermo P. Prevalence of oral soft tissue lesions related to mechanical tooth cleansing procedures. *Community Dent Oral Epidemiol* 1976;4(2):77–83.
5. Rustogi KN, Triratana T, Kietprajak C, Lindhe J, Volpe AR. The association between supragingival calculus deposits and the extent of gingival recession in a sample of Thai children and teenagers. *J Clin Dent* 1991;3 (Suppl. B):112-114.
6. Loe H, Anerud A, Boysen H. The natural history of periodontal disease in man: prevalence, severity and extent of gingival recession. *J Periodontol* 1992; 63(6):489-495.
7. Powell RN, McEniery TM. Disparities in gingival height in the mandibular central incisor region of children aged 6– 12 years. *Community Dent Oral Epidemiol* 1981;9(1):32–36.
8. Mohan R, Agrawal S, Gundappa M. Atomic force microscopy and scanning electron microscopy evaluation of efficacy of scaling and root planing using magnification: A randomized controlled clinical study. *Contemp Clin Dent* 2013;4(3):286-94.
9. Serino G, Wennstrom JL, Lindhe J, Eneroth L. The prevalence and distribution of gingival recession in subjects with a high standard of oral hygiene. *J Clin Periodontol* 1994;21(1):57-63.
10. Jshipura KJ, Kent RL, DePaola PF. Gingival recession: intraoral distribution and associated factors. *J Periodontol* 1994;65(9):864-871.
11. Bouchard P, Malet J, Borghetti A. Decision-making in aesthetics: root coverage revisited. *Periodontol* 2000;27: 97–120.
12. Wennstrom JL. Mucogingival therapy. *Ann Periodontol* 1996;1(1):671–701.
13. Grupe HE, Warren RF. Repair of gingival defects by a sliding flap operation. *J Periodontol Online* 1956;27(2): 92-95.
14. Cohen DW, Ross SE. The double papillae repositioned flap in periodontal therapy. *J Periodontol* 1968;39(2):65 – 70.

Corresponding Author

Dr. Ranjana Mohan
Professor & Head
Department of Periodontics
Teerthanker Mahaveer Dental College & research Centre,
Moradabad
Email Id.: - ranjanamohan16@yahoo.com